

Cholera

Just an Upset Stomach?

An unfamiliar pathogen attacks unsuspecting passengers on a jetliner

NOT LONG AFTER LANDING, AN ATTENDANT ON Flight 386 knew something was wrong. Between gurgles, pings, and cramps, her gut felt like a punching bag. She quickly disappeared into the lavatory.

Meanwhile, in a different part of town, a passenger from the same flight was also in distress. Her bowels were running like water. Suddenly it dawned on her: This intestinal bug was out of control.


In a third house in the sprawling metropolis, a 70-year-old man who had just flown 6,000 miles to visit his family checked his shaving kit to see if his diarrhea pills were still there. Well, maybe he should take a couple: This illness was worse than usual.

Three days later, the flight attendant and the sightseer were recovering. The grandfather was dead.

IN JANUARY 1991, EPIDEMIC CHOLERA SURFACED in South America for the first time in the 20th century. Originating in coastal Peru and rippling inland, the toxic tide reached 14 Latin American countries and spread as far north as Mexico, infecting nearly half a million residents and killing 4,000.

But on Valentine's Day 1992, cholera was the last thing on the minds of the 356 passengers and crew on Aerolineas Argentinas Flight 386. The flight had been uneventful, departing Buenos Aires, Argentina, stopping in Lima, Peru, and then landing in Los Angeles. But 24 hours later, diarrhea struck six of its passengers. On February 16, 25 more were affected. By February 17, the toll was up to 54 infected and one dead.

Sometimes I wonder if those early sufferers realized they were part of an outbreak. They certainly had no way to compare notes, dispersed halfway around the globe. On February 19, however, five Los Angeles-area hospitals reported stool cultures growing the bacterium *Vibrio*



A 1912 illustration from a French magazine dramatized the toll an old disease took on Turkish troops during the Balkan Wars. In modern times, it killed 20,000 refugees during the 1994 civil war in Rwanda.

cholerae—all from travelers on Flight 386. That's when the warning bell sounded, and county health officials knew they had to try to find the remaining 351 passengers and crew. From a medical standpoint, they were late. Although most cholera patients suffer only mild to moderate diarrhea, others have been known to drop dead in a day.

There was a second reason to track the entire planeload of people. In order to

pinpoint the source of the outbreak—presumably cholera-laced food served on board—health authorities had to survey as many passengers as possible, both with and without symptoms. At the same time, another question gnawed: Could public-health detectives find the tainted food before other flights were exposed?

In Los Angeles, the crisis couldn't have come at a worse time. On the same weekend the cases broke, a fire closed the

downtown offices of the county's acute communicable disease unit. In makeshift quarters miles from home, the frontline squad launched an investigation without computers, files, or phones. Looking back, the unit's chief, Laurene Mascola, recalls one silver lining. "The good thing... was that all of us were in one big, open area. And so we worked very efficiently, as we had few other distractions."


They still faced a tall order: reviewing customs declaration forms to identify heads of household on the flight, calling and faxing to determine who else was on board, talking to crew members (this required delicate negotiations with the airline), and cajoling caterers in Buenos Aires and Lima for menus, all the while juggling daily press conferences with news-hungry reporters.

Somehow, the wobbly effort succeeded. When investigators finally reached the sick and the well, compared their food diaries, and tested their lab samples, a shrimp salad prepared in Lima was the smoking gun. The other good news? Only Flight 386 had served the microbe-laden dish. On the other hand, of 194 passengers and crew who submitted blood or stool samples, 100 had undeniable evidence of recent cholera infection.

As a tropical-medicine specialist, I first heard about the rash of cholera from newspapers. It was a big story because the circumstances of the outbreak were so unusual. Nobody expects to get cholera on an airplane.

The disease typically occurs in regions where diarrheal illnesses spread easily because of inadequate sanitation. As many as 2 million infants and toddlers in developing countries still succumb to diarrhea every year. Most of these deaths are not from cholera, however. While the intestinal pathogens *Rotavirus* and toxin-producing *Escherichia coli* are pervasive in hygiene-poor countries, cholera is more often a sporadic wildfire that snakes through high-risk settings and even crosses oceans. When it's not wreaking havoc in a favela or a refugee camp, the organism's usual survival strategy is to hide out in brackish waters affixed to the horny exoskeletons of plankton and shellfish, an ancient form of bacterial hibernation.

What cholera and harmful *E. coli* have



Cholera-causing bacteria hitchhike around the world on the backs of millimeter-long crustaceans called copepods (above).

in common is a poison (also known as an enterotoxin) that binds to the inner lining of the small intestine. As a result, fluid and electrolytes are secreted rather than absorbed, and the affected gut gushes like a broken fire hydrant. Cholera toxin in particular is so potent that some victims purge as much as a liter per hour of nearly clear diarrhea, known to medical officers during the British raj as rice-water stool. Even today, if patients in this subgroup don't receive intravenous fluids or down

training program. "How would you like to discuss a case of traveler's diarrhea in next week's Grand Rounds?" he asked.

"Sure," I said. "Just fax me the write-up."

Soon I was reading about a middle-aged woman who had recently returned from El Salvador. On her flight to Los Angeles, she developed abdominal pain, vomiting, and profuse, watery diarrhea. After three days, too weak to even hold up her head, she was brought to the hospital. Her lab values told the rest of the story. Her blood was highly concentrated, her potassium dangerously low, and her kidneys had nearly shut down.

This has got to be cholera, I thought. I wonder how the residents handled the case?

The following week, my question was answered when two young doctors-in-training stepped to the podium. What they described next would make any residency director glow with pride. Suspecting cholera from the outset, they infused six liters of an intravenous glucose-electrolyte solution known as Ringer's lactate solution, inserted a urinary catheter and a rectal tube, and then meticulously charted *I's* and *O's* (medicalese for "intake" and "output") through all orifices in order to

The affected gut gushes like a broken fire hydrant. This toxin is so potent that some victims purge as much as a liter per hour

massive amounts of a glucose-electrolyte solution like that found in popular sports drinks, they can die from desiccation.

Sadly, the grandfather from Flight 386 turned out to be a textbook example of a worst case. Three days after becoming infected, his blood pressure became dangerously low, his pulse weak and thready, his bowel bulging with fluid, while paradoxically, his oral membranes were so dry that one examiner's tongue depressor stuck to the roof of his mouth. By the time he reached an intensive care unit, he was comatose, and his tissues were dangerously acidic. Despite heroic rescue efforts, he died within hours.

SEVERAL YEARS LATER, I RECEIVED A PHONE CALL from the director of a nearby family-practice


replace the exact amount of fluid needed. They also started doxycycline, an antibiotic that lessens cholera's overwhelming fluid loss as well as its bacterial stool count. Their management was flawless. Slowly, the patient's kidneys began to work again, and her diarrhea abated. Five days later, the patient walked out of the hospital vibrant and well.

Of course, a little credit also goes to Flight 386. Where I live, it made cholera a household word. ☐

Claire Panosian Dunavan is a tropical and infectious diseases specialist at the David Geffen School of Medicine at the University of California at Los Angeles. The cases described in *Vital Signs* are based on true stories. Some details have been changed to protect patients' privacy.

Schistosomiasis

VITAL SIGNS



stoned, eroded. Forget that. Under the microscope, he's loaded with worms."

Worms—including roundworms, tapeworms, and flukes—hold a special place among the human body's invaders. For one thing, they're big, measuring anywhere from one quarter of an inch to more than three feet. They also exploit nature, sometimes using intermediate hosts like fish and snails to further their life cycles. And once they've made their way into a host, many species have sex and lay eggs.

When I looked at the major's biopsies, I could see male and female worms entwined in the intestinal tissue. Deposited nearby were rust-brown worm eggs with lateral spines. With a little imag-

Left: The blood fluke, *Schistosoma mansoni*, uses two suckers to attach to intestinal blood vessels in humans.

Just a Fluke?

When a sick stomach won't go away, a good patient history can help

WITH HIS DARK HAIR, BURNT-SIENNA SKIN, AND FLASHING TEETH, HE LOOKED LIKE an actor off the set of *Lawrence of Arabia*. In fact, he was a career military man far from home. Major Ali Al Rahim was a Saudi Arabian pilot assigned to two years of elite training at an air base in southern California. He was pleased with his posting, but he had a problem: unrelenting cramps and diarrhea. "Could it be the food?" he wondered. Some days after lunch he shuffled from flight lab to lavatory nearly every hour.

The major's gut had plagued him for years, but never like this. After seeing the base medic, he began taking anti-motility drugs. But the problems didn't go away, so he returned to the clinic time and again. Then he showed up one day with a tender belly and a bloody stool.

That's when an official request went forth. Would the Saudi consul OK a visit with Mark Griffin, a top gas-

troenterologist at the university hospital where I work? Yes, the answer came back. One week later, Mark performed Major Al Rahim's colonoscopy. The next day, I was paged.

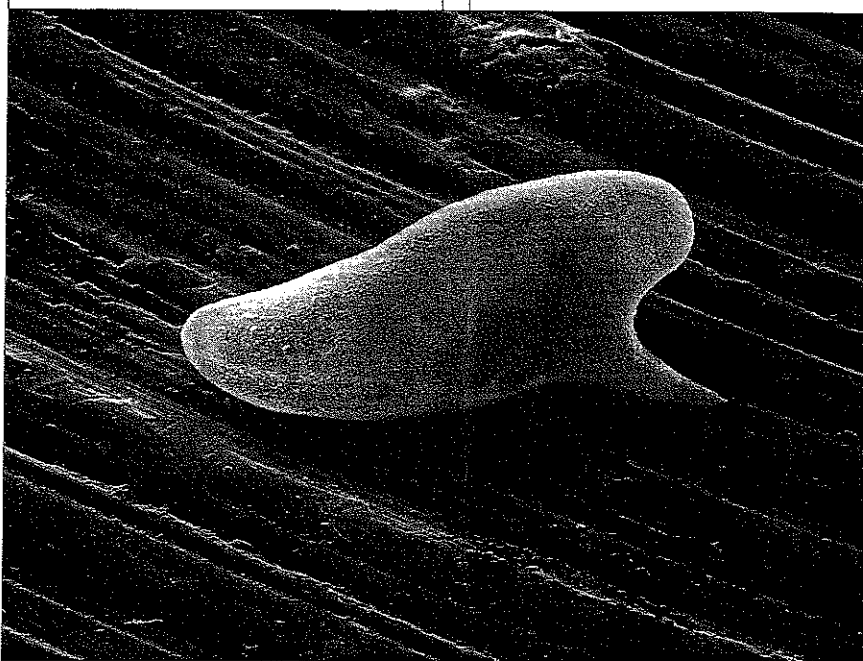
"Claire, you won't believe it when you see this guy's biopsies," Mark said. "At first when I scoped him, I thought his mucosa was a dead ringer for ulcerative colitis: hemorrhagic, cobble-

ination, the eggs looked like human heads with beaked noses pointed sideways.

To a parasitologist like me, that profile is the hallmark of just one species: *Schistosoma mansoni*. The biopsies offered living proof: Major Al Rahim was infected with a strain of fluke that, together with four related species, constitutes the world's most deadly worm scourge. Currently, there are some 200 million people with schistosomiasis worldwide. And because water development projects such as dams and irrigation systems actually aid schistosomes' spread, the number of infected people in developing countries may rise in coming decades.

Freshwater is the prime milieu of schistosomes. Consider the fate of schistosome eggs passed in stool. If an infected human defecates in or near freshwater, the eggs rupture, releasing embryos. Propelled by microscopic beating hairs called cilia, the embryos home like stealth bombs to freshwater snails. Once invaded, the snails transform into parasite hatcheries that over the ensuing weeks produce thousands of fork-tailed baby schistosomes. The newborns, called cercariae, have up to 48 hours to penetrate human skin or die trying. →

The severity of schistosomiasis varies: Some 120 million people have no symptoms, 60 million have moderate illness, 20 million have severe disease. An estimated 80 percent of all schistosomiasis cases—and all of the most severe—are concentrated in Africa, mostly in the sub-Saharan nations.



The barb on this schistosome egg may help it move from the blood into tissue.

→ Now picture life in the tropics, where schistosomes thrive. Countless human pastimes—bathing, fishing, washing clothes—entail water contact. If cercariae are nearby, they can breach the skin in just three to five minutes, no cut or crack required. They then pierce capillaries and bodysurf the bloodstream to reach their beachhead: the veins lining the human bladder and gut.

Adult schistosomes measure a quarter to three quarters of an inch long. Most dwell in humans for five to 10 years, although a hardy few survive two or three decades. Whether short- or long-lived, they copulate nonstop once settled into their venous burrows. Except, that is, when the female fluke briefly detaches from the male's vertical cleft (the "schist") to lay eggs. A mature, partnered *S. mansoni* female deposits 100 to 300 eggs per day.

In considering Major Al Rahim's case, schistosome eggs were my real worry. Like buckshot, they scatter through the abdomen and pelvis, sometimes also lodging in the lungs, brain, and spinal cord. Surrounding each egg are pinpoints of inflammation that eventually coalesce into scars. When a human has been infected with schistosomes for years, the end result can be pain, blood-

tinged urine, diarrhea, a swollen liver and spleen, and—in the worst case scenario—dilated esophageal veins called varices that can spurt like oil wells. With Major Al Rahim's heavy worm load, I figured his tissue egg counts were astronomical. Any complication was possible. And so I took extra care performing his physical examination.

"Does it hurt here?" I asked when I got to his lower abdomen. The major answered with a wince as I pressed right over his inflamed colon. Then my fingers came upon the fleshy peninsula of an enlarged liver extending below his ribs on the right. Inwardly, I grimaced. The evidence for advanced inflammation of the liver and spleen—the chronic immune response to the schistosome eggs—was growing stronger.

"First we'll do a baseline abdominal CT scan," I told the major, "then we'll order up your pills."

In most parts of the world affected by schistosomiasis, X rays and scans have little place in managing the dis-

ease. The best use of limited health care resources in such settings is simply mass treatment. Every six to 12 months, for example, groups of Egyptian schoolchildren in the Nile delta receive praziquantel, a safe and effective antihelminthic drug given by mouth.

Our technology-rich health care system in the United States, however, operates differently. When we're treating patients with exotic ailments, high-tech resources can sometimes teach us new lessons about old diseases.

That was my reasoning when I sent Major Al Rahim for a full scan of his intra-abdominal organs. As I'd expected, his liver was diffusely scarred and his spleen was twice the normal size. Left untreated, his illness could easily progress within a few years to full-blown esophageal varices and fatal hemorrhage. Because the major could be assigned anywhere around the world, I worried where he might be when the dam broke.

I treated the major with two courses of praziquantel, and months later I repeated his scan. Much to my amazement, his swollen organs looked normal. For the first time in nearly a year, he said, his diarrhea and cramps were gone. Finally he could focus full attention on his military assignment. And yes, he assured me, he would continue taking praziquantel over the next several years to wipe out the final traces of the worms.

At that point, my job was done. But one nagging question remained. How on Earth, I asked, did Major Al Rahim pick up schistosomiasis in the first place? After all, he had grown up in a desert.

"Yes, of course," the major said, with a grin, "the earth was dry most of the year. But, remember, my home was also an oasis. When the waters came, like any boy, naturally I splashed and played."

Ah, yes. Mystery solved. ☐

THE CASE DESCRIBED IN VITAL SIGNS IS BASED ON A TRUE STORY. SOME DETAILS HAVE BEEN CHANGED TO PROTECT THE PATIENT'S PRIVACY.

THE DOCTOR IS IN

Claire Panosian Dunavan is a professor of infectious diseases at the UCLA School of Medicine. As director of UCLA's Travel and Tropical Medicine Clinic, she diagnoses a handful of advanced schistosomiasis cases in foreign-born patients every year. Fortunately, she adds, with today's sensitive blood tests, any travelers who suspect they've recently been infected can easily get a diagnosis and treatment.